

Safety and Efficacy of the Combined Use of Ivermectin, Dexamethasone, Enoxaparin and Aspirina against Covid-19 the I.D.E.A. Protocol

Carvalho Hector^{1*}, Hirsch Roberto²

¹Department of Internal Medicine, Universidad Abierta Internamericana, San Juan, Argentina; ²Department of Infectology, Universidad de Buenos Aires, Caba, Argentina

ABSTRACT

From the first outbreak in Wuhan (China) in December 2019, until today (05/28/2020), the number of deaths worldwide due to the coronavirus pandemic exceeded 2.5 millions.

Only in Argentina, 50,000 deaths have been confirmed so far. There haven't been so far any clear diagnostic pattern for this exceptional entity except unilateral skin involvement, early onset of symptoms, positive ANA and negative tests for *Borrelia burgdorferi*. Hence, we report a new case of a young Moroccan man.

No treatment tested worldwide has shown unquestionable efficacy in the fight against COVID 19, according to W.H.O, NIH and NICE reports and accumulated data.

Our proposal consists of the combination of drugs, based on the pathophysiology of the virus. We have designed a treatment called I.D.E.A., based on four affordable drugs already available on the pharmacopoeia in Argentina, on the following rationale:

- Ivermectin (IVM) solution to lower the viral load in all stages of COVID 19
- Dexamethasone 4-mg injection, as anti-inflammatory drug to treat hyperinflammatory reaction to COVID-infection
- Enoxaparin injection as anticoagulant to treat hypercoagulation in severe cases.
- Aspirin 250-mg tablets to prevent hypercoagulation in mild and moderate cases

Except for Ivermectin oral solution, which was used in a higher dose than approved for parasitosis, all other drugs were used in the already approved dose and indication. Regarding Ivermectin safety, several oral studies have shown it to be safe even when used at daily doses much higher than those approved already. A clinical study has been conducted on COVID-19 patients at Eurnekian Hospital in the Province of Buenos Aires, Argentina. The study protocol and its final outcomes are described in this article. Results were compared with published data and data from patients admitted to the hospital receiving other treatments.

None of the patient presenting mild symptoms needed to be hospitalized. Only one patient died (0.59 % of all included patients vs. 2.1 % overall mortality for the disease in Argentina today; 3.1 % of hospitalized patients vs. 26.8 % mortality in published data). I.D.E.A. protocol has proved to be a very effective alternative to prevent disease progression of COVID-19 when applied to mild cases, and to decrease mortality in patients at all stages of the disease with a favorable risk-benefit ratio.

Keywords: Ivermectin; Aspirin; Dexamethasone; Enoxaparin; Covid-19; I.D.E.A.

Correspondence to: Carvalho Hector, Department of Internal Medicine, Universidad Abierta Internamericana, San Juan, Argentina, E-mail: hymcarvalho@hotmail.com

Received date: February 16, 2021; **Accepted date:** March 26, 2021; **Published date:** March 31, 2021

Citation: Hector C, Roberto H (2021) Safety and Efficacy of the Combined Use of Ivermectin, Dexamethasone, Enoxaparin and Aspirina against Covid-19 the I.D.E.A. Protocol. J Clin Trials. 11:459.

Copyright: © 2021 Hector C, et al. This is an open access article distributed under the terms of the Creative Commons Attribution License, which permits unrestricted use, distribution, and reproduction in any medium, provided the original author and source are credited.

INTRODUCTION

In late December 2019, the incidence of atypical pneumonia cases of unknown cause was reported in the Chinese city of Wuhan.

PCR (Polymerase Chain Reaction) studies found a coronavirus, which was >85% similar to a bat SARS-type CoV (bat-SL-CoVZC45).

SARS-type CoV (bat-SL-CoVZC45)

The early association identified between SARS-CoV with SARS-CoV-2 was supported by subsequent analyzes, where an important similarity in these transmembrane structures was made clear.

The only significantly different portion is a furin-binding domain in the SARS-CoV-2 protein S, which may expand tropism or increase virus transmission.

Studies on SARS-CoV proteins have revealed a potential role for IMP α / β 1 during infection in the signal-dependent nucleocytoplasmic closure of the SARS-CoV nucleocapsid protein, which may affect host cell division. The predilection and competitiveness of the virus over ACE2 cell receptors has already been demonstrated, and its subsequent need for the importin described above is also confirmed. This functional receptor is found in multiple tissues, including alveolar epithelium of the lung, arterial and venous endothelium, smooth muscle, renal tubular epithelium, oropharyngeal mucosa and epithelium of the small intestine, largely explaining the clinical presentation of patients with COVID-19. So has its interaction with TMPRSS2 receptors (Figure 1).

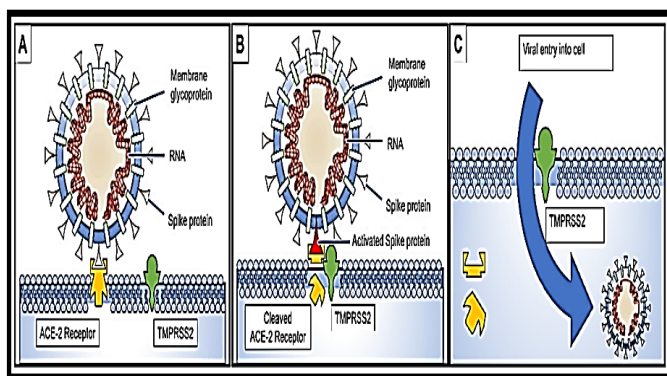


Figure 1: COVID 19 and ACE2 receptors

DEVELOPMENT OF CLINICAL EVENTS

Before proceeding to list them, we must emphasize two premises:

Between 30 and 50% of patients who contract COVID 19 will be asymptomatic or oligosymptomatic. This fact will not give rise to the consultation, and will directly affect a notorious under-registration of the cases.

The second, even more disturbing, premise is that these patients are as contagious as the moderate and severe cases.

The virus incubation period has been calculated at 5.1 days (95% CI, 4.5 to 5.8 days), and 97.5% of patients are said to have symptoms at 11 days (95% CI 8.2 to 15.6 days).

A mortality of 3.1 % has been calculated.

The average COVID patient presents with fever (78%), cough (60-79%) and myalgias or fatigue (35.8 to 44%).

55% develop dyspnea, which appears on average 8 days after the onset of symptoms.

To the manifestations expressed above, the presence of bilateral conjunctival injection should be added, without associated secretions, hyposmia, skin rash and hyposmia.

Diagnostic confirmation is made through laboratory studies, which can be performed on a wide variety of biological samples.

Bronchoalveolar lavage samples showed the highest sensitivity (93%), followed by sputum samples (72%), nasal swabs (63%), fiberoptic brush biopsy (46%), pharyngeal swabs (32%), feces (29%) and, finally, blood (1%). A sensitivity of 91% is reported in saliva samples.

Computed Axial Tomography (CAT) is very useful as a complementary study in the diagnostic approach of COVID-19, but this does not discredit follow-up by conventional Radiology, if more sophisticated means are not available.

Evidence suggests that a subgroup of patients with severe forms of COVID 19 may have cytokine storm syndrome.

Therefore, we recommend the identification and treatment of hyperinflammation using existing approved therapies with proven safety profiles to address the immediate need to reduce increasing mortality (see Therapeutic Proposal).

Secondary Hemophagocytic Lymphohistiocytosis (SHLH) is a poorly recognized hyperinflammatory syndrome characterized by fatal and fulminant hypercytokinemia with multiple organ failure.

In adults, SHLH is most often triggered by viral infections, and occurs in 3.7-4.3% of sepsis cases.

The cardinal features of sHLH include constant fever, cytopenias, and hyperferritinemia; Pulmonary involvement (including ARDS) occurs in approximately 50% of patients.

A cytokine profile that resembles sHLH is associated with the severity of COVID-19 disease, characterized by an increase in interleukin (IL) -2, IL-7, granulocyte colony stimulating factor, protein 10 inducible by interferon- γ , monocyte chemoattractant protein, macrophage inflammatory protein 1- α and tumor necrosis factor- α .

Mortality predictors from a recent multicenter retrospective study of 150 confirmed cases of COVID-19 in Wuhan, China included elevated ferritin (mean 1297.6 ng / ml in non-survivors versus 614.0 ng / ml in survivors; $p < 0.001$) and IL-6 ($p < 0.0001$), suggesting that mortality could be due to viral hyperinflammation (Figure. 2).

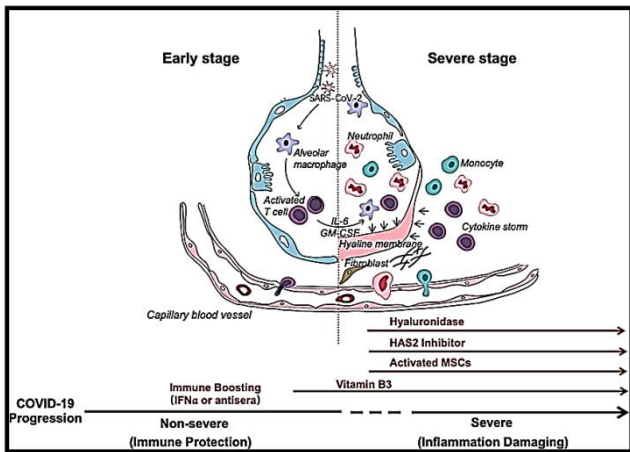


Figure 2: Aggressive forms of infection.

However, cases have been reported where tissue and organ involvement has been found whose concentration of ACE receptors is very dissimilar (myocardium, brain). In all of them, the common denominator was small vessel thrombosis, as seen in entities such as Catastrophic Antiphospholipidic Syndrome.

More than a century ago, Virchow proposed that the formation and spread of thrombi was caused by abnormalities in three key areas:

Blood flow

The vascular wall

The components of blood

These three factors are known as the Virchow triad (Figure.3).

Currently the Virchow triad factors have been narrowed down in more detail:

Circulatory stasis: abnormalities of hemorrheology and turbulence in vascular bifurcations and stenotic regions.

Injury to the vascular wall: abnormalities in the endothelium, such as atherosclerosis and associated vascular inflammation.

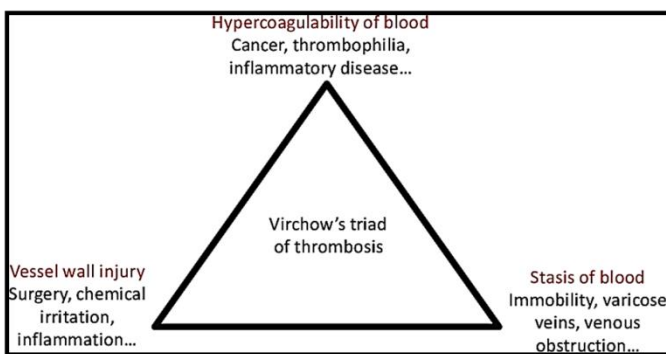


Figure 3: Updated virchow triad.

Hypercoagulable state: Abnormalities in the coagulation and fibrinolytic pathways and in platelet function associated with an increased risk of VTE and other cardiovascular diseases (such as Coronary Artery Disease [CPA], heart failure and stroke in patients with AF). All lead to a state of hypercoagulability, which could explain the formation of microthrombosis in different locations, As has been repeatedly reported in patients with COVID 19.

BASES OF THE PROPOSED THERAPEUTICS

They rest on four pillars: Ivermectin, Aspirin, Dexamethasone and Enoxaparin.

IVERMECTIN

Ivermectin is a broad-spectrum antiparasitic, with vermucidal and ectoparasiticidal properties. It was discovered and marketed for animal use in the early 1980s.

Approved in 1997 by the FDA for single-dose strongyloidiasis of 200 mcg /kg and crusted scabies (Scabies Norway) in patients with AIDS at a dose of 200 mcg/kg, every week for 2 weeks.

In Argentina, it has been available for human use for almost 20 years.

But, much more recently, its viricidal effects have been compiled on different varieties of flavivirus, dengue, Zika, Chikunguña, etc.

Ivermectin has been reported to be a SARS-CoV-2 inhibitor. This activity is believed to be due to the dependence of many different RNA viruses on IMPα/β1 during infection. These reports suggested that the inhibitory activity of ivermectin nuclear transport may be effective against SARS-CoV-2, since they demonstrate that ivermectin has antiviral action against the clinical isolate of SARS-CoV-2 in vitro, with a single dose capable to control viral replication in 24-48 hours in vitro.

Apart from the intracell effect of IVM, more mechanisms of action have been described (Figure 4).

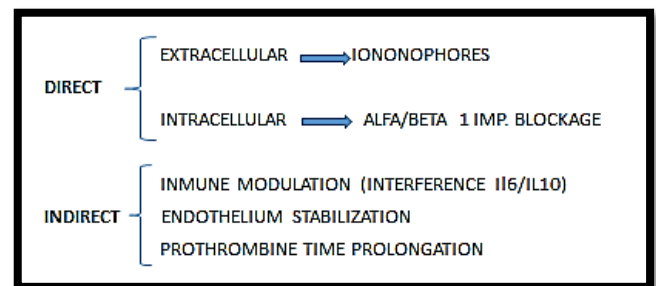


Figure 4: Invermectin mechanisms of action against covid infection.

Although in vitro studies have used doses that -extrapolated to those recommended in the treatment of ectoparasitosis in humans- might seem high, the truth is that studies carried out in healthy volunteers, more than two decades ago, proved that the usual doses they can be increased tenfold, without significant side and / or adverse effects.

ASPIRIN

Aspirin is the common name for acetylsalicylic acid. The chemical production is based on the salicylic acid obtained by synthesis. Its most common uses and for what it was first used was as an analgesic (for pain), antipyretic (to lower fever) and anti-inflammatory. It is classified as a non-steroidal anti-inflammatory drug (NSAID). In 1989 the first large study was published that proved that Aspirin reduces cardiovascular risk, acting as an antiplatelet agent.

These were low-dose Aspirin, and the risk of myocardial infarction was found to decrease by 44% when the previously named dose of Aspirin was administered.

HEPARIN AND ENOXAPARIN

Heparins are injectable anticoagulant substances. A distinction should be made between standard heparin or unfractionated heparin (HNF) and low molecular weight heparins (LMWH).

HNF is made up of a heterogeneous mixture of polysaccharide

chains of variable length.

LMWHs are the result of fragmentation of HNF by different methods to achieve products with lower and more homogeneous molecular weights. They are also made up of a mixture of polysaccharide chains and their average molecular weight is much lower. The antithrombotic and anticoagulant activity of HNF is related to the ability to inhibit factor Xa and factor IIa respectively. LMWHs have less inhibitory activity to thrombin or factor IIa but maintain the same potency with respect to factor Xa, so it is expected that they present a lower risk of bleeding but the same antithrombotic activity.

CORTICOSTEROIDS

Systemic corticosteroids are powerful anti-inflammatory and immunosuppressive agents. They can be administered intravenously, intramuscularly, orally, intralesionally, and topically. Its side effects increase with high, long and frequent doses.

Corticosteroids are drugs frequently used in various clinical situations, because they are powerful anti-inflammatories and immunomodulators.

Glucocorticoids passively diffuse through the cell membrane, then join soluble receptor proteins in the cytoplasm. They are used, among others, for the treatment of some rheumatic diseases. A separate case, well known but not studied in the current contingency, is acute adrenal insufficiency. The RECOVERY Trial proved DM is useful to reduce mortality.

MINOR CRITERIA	MAJOR CRITERIA
Fever less than 38.5 °	Fever higher than 38.5 °
Isolated diarrheal episodes	Diarrhea (more than 3 diarrheic stools / day)
Hyposmia or Hypogeusia	Flictenular conjunctivitis
Mild desaturation (between 96 and 93%)	Strong desaturation (less than 92%)
Dyspnea without matter	Tachypnea (FR > 25 / minute)
Polymyoarthralgias	Livedo reticularis
Persistent headache	Giant urticaria
Abdominal pain	

Table 1: Criterias.

I.D.E.A. TRIAL

Based on the precedent data, we performed a Clinical Trial based on the above-mentioned four drugs, on a gradual scale, and according the severity of each case That Trial, and its outcomes, were duly submitted to the National Library of Medicine (USA) in July 2020. It consisted in a prospective, two-arms (not randomized but based on consentments), study. The control group received all the other options available (hydroxicloroquine, lopinavir-ritonavir, convalescent plasma, etc.). In order to determine the dose and combination, we developed our own severity score.

INTERPRETATION

Mild cases	Moderate cases	Severe cases
Only minor criteria findings	3 major crit. findings, or 2 major + 2 minor	4 major crit. Findings or 3 major + 2 minor

Table 2: Interpretation.

Disease severity	Ivermectin	Corticoid		Ventilation
Firm Suspicious Case or Confirmed case	24 mg orally at a dose of 200 ug / kg in a single dose, to be repeated a week later	No	Aspirin 250 mg orally	No
Moderate clinical stage	36 mg orally at a dose of 400 ug / kg in a single dose, to be repeated a week later	Dexamethasone 4 mg (parenteral)	idem	Low Flow Washed Oxygen or Oxygen Concentrator
Severe case with bilateral pneumonia	48 mg via gastric cannulae, at a dose of 600 ug/kg in a single dose, to be repeated a week later	idem	Enoxapar in 100 UI/kg (1 mg/kg)	Mechanical Ventilation

Table 3: Disease severity.

EQUIVALENCES

Dose of 300 micrograms/kg orally, 0.6% drops=1.5 drops/kg of weight

Dose of 400 micrograms/kg orally, 0.6% drops=2.25 drops/kg of weight

Dose of 600 micrograms/kg orally, 0.6% drops=3 drops/kg of weight

When possible, we preferred to use IVM solution instead of tablets, because of its easier absorption and the velocity to reach Tmax and tissue concentration. Solution is also a better alternative if gastric cannulae shall be used.

OUTCOMES

According to our clinical criteria, patients were divided into two major groups: outpatients and admitted patients. Among the admitted patients (Figure 5), death rate was 7 times less with the I.D.E.A. protocol, if compared to all other applied treatments. In this case, it is important to mention that corticosteroids and or enoxaparin were used on both arms.

It is important to emphasize that death was taken as final “adverse reaction”, thus avoiding any subjective bias.

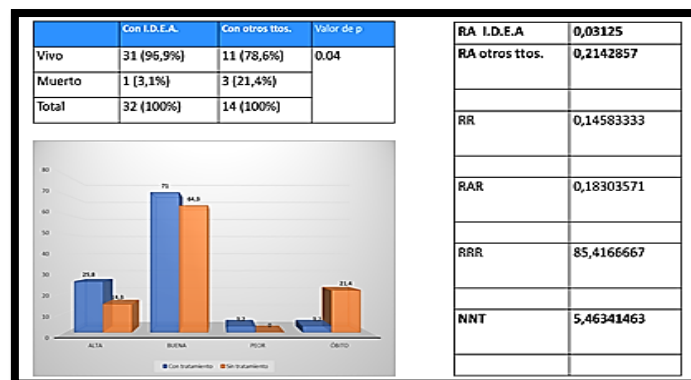


Figure 5: Outcomes in admitted patients.

In the outpatients' group, the adverse effect considered was the need of ulterior admittance, as it has been observed worldwide that this happens in up to 10 % of the mild cases, during the two weeks posterior to diagnosis.

None of those 135 patients (0,0 %) needed to be admitted (Fig. 6)

Total:
135 patients with + swabs but without admittance criteria
Average Age: 53.5 years
Sex Predominance : not significative
Medication:
 Ivermectin 24 mg. oral, to be repeated a week later
 AAS 250 mg. oral, on a daily basis
Need of ulterior admittance: zero

Figure 6: Mild cases outcomes.

CONCLUSION

Given the rapid advance of the pandemic, the sequel of death that it leaves behind, the lack of sustainable evidence in the experimental treatments proposed up till now, the presence of all the drugs proposed by us in the national pharmacopoeia, their low cost in relation to the other trials, the scarce incidence of side effects, and the possibility of massive use without the limitations of dose, we conclude that the combination ivermectin + aspirin + dexamethasone + enoxaparin is a very desirable alternative.

Since we finished our Trials, 54 more ones have been submitted to the NLM (USA), 35 of which already contain results. A meta-analysis of those 37 Trials concluded all of them had positive results, and the possibility of bias was almost inexistent (Figure 7).

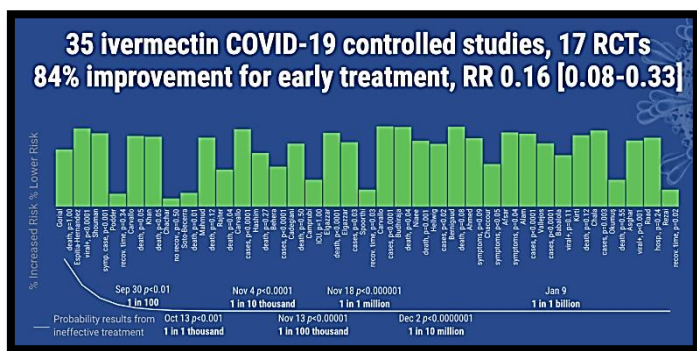


Figure 7: Meta-Analysis of trials using Ivm.

ACKNOWLEDGEMENT

This Trial received no public or private funding.

Conflict of Interest

The Authors manifest no conflict of interests.

REFERENCES

1. AJ Rodriguez-Morales, JA Cardona-Ospina: Clinical, laboratory and imaging features of COVID-19: A systematic review and meta-analysis Travel medicine and Infectious Disease. 2020.

2. P Mehta, DF McAuley, M Brown, E Sanchez: COVID-19: consider cytokine storm syndromes and immunosuppression. The Lancet. 2020.
3. Haruhiko Ogawa: The procoagulant pattern of patients with COVID-19 acute respiratory distress syndrome. Journal of thrombosis and haemostasis. 2020.
4. Ning Tang: Anticoagulant treatment is associated with decreased mortality in severe coronavirus disease 2019 patients with coagulopathy' Journal of thrombosis and haemostasis. 2020.
5. Jean M. Connors and Jerrold H. Levy: Thromboinflammation and the hypercoagulability of COVID-19. Journal of thrombosis and haemostasis. 2020.
6. Hirsch, R. Potential benefits of aspirin and enoxaparin in COVID 19 cases (personal communication). 2020
7. Anetta Undas et al. Antithrombotic properties of aspirin and resistance to aspirin: beyond strictly antiplatelet actions. Review Article. Blood. 2007 Mar 15; 109(6): 2285–2292.
8. Buchanan MR, Hirsh J. Effect of aspirin on hemostasis and thrombosis. N Engl Reg Allergy Proc. 1986;7 (1):26-31.
9. Ignasi Rodríguez-Pintó et al.: The effect of triple therapy on the mortality of catastrophic anti-phospholipid syndrome patients Rheumatolo. 2018;57(7):1264–1270.
10. NICE COVID-19 rapid evidence summary: angiotensin-converting enzyme inhibitors (ACEIs) or angiotensin receptor blockers (ARBs) in people with or at risk of COVID-19
11. Batya Swift Yasgur: More evidence hydroxychloroquine is ineffective, harmful in COVID-19. 2020.
12. Colette DeJong, MD1; Robert M. Wachter: The Risks of Prescribing Hydroxychloroquine for Treatment of COVID-19—First, Do No Harm. JAMA Intern Med. 2020.1853.
13. Bin Cao et al. A Trial of Lopinavir–Ritonavir in Adults Hospitalized with Severe Covid-19 May 7, 2020 N Engl J Med 2020; 382:1787-1799.
14. Neil M. Ampel et al.: Lopinavir-Ritonavir Was Not Effective for COVID-19 N Engl J Med 2020.
15. Ed Silverman, Adam Feuerstein, and Matthew Herper: New data on Gilead's remdesivir show no benefit for coronavirus patients. 2020.
16. ClinicalTrials.gov Tocilizumab in the Treatment of Coronavirus Induced Disease (COVID-19) (CORON-ACT) Sponsor: University Hospital Inselspital, Berne Information provided by (Responsible Party): University Hospital Inselspital, Berne. 2020.
17. L. Bielory: Clinical complications of heterologous antisera administration. Journal of Wilderness Medicine 2, 127-139 (1991) Division of Allergy & Immunology, UMDNJ - New Jersey Medical School. 1991.
18. Ziegler CGK et al. SARS-CoV-2 receptor ACE2 is an interferon-stimulated gene in human airway epithelial cells and is detected in specific cell subsets across tissues. Cell.
19. Jairo Victoria Ch.: Ivermectina nuevos usos de una vieja droga; revisión. Revista Asociación Colombiana de Dermatología y Cirugía Dermatológica. Volumen 7, número 1, febrero de 1999.
20. F Giovannoni: Rol antiviral intrínseco de PML en la infección con flavivirus - 2018 - ri.conicet.gov.ar. 2018.

21. L Del Carpio Orantes: NS2B-NS3-Zika, therapeutic white for zika infection - EC Microbiol. 2017.
22. MV Palmer, WC Stoffregen West Nile Virus Infection in Reindeer (*Rangifer Tarandus*) - Journal of Infectious dis., 2004.
23. Gubler DJ. The continuing spread of West Nile virus in the western hemisphere. Clin Infect Dis. 2007 Oct 15;45 (8):1039-46. Epub. 2007.
24. Chilhinh Nguyen et al.: Evaluation of a novel West Nile virus transmission control strategy that targets *Culex tarsalis* with endectocide-containing blood meals. 2019
25. Ivermectina: sus múltiples usos, seguridad y toxicidad JV Ch - 2010 - sochiderm.org
26. TP de Castro, DPF Duarte, DP Carvalho: Estudo preliminar sobre os efeitos clínicos do tratamento da Febre Chikungunya aguda usando Ivermectina como fármaco antiviral. - ampe-med.com. 2017.
27. Botargues M, Enz P, Musso C.: Tratamiento con corticoides. Evid Act. Pract Ambul. 14 33-36 Ene-Mar 2011.
28. Leon Caly; Julian D. Druce; Mike G. Catton; David A. Jans; Kylie M. Wagstaff The FDA-approved Drug Ivermectin inhibits the replication of SARS-CoV-2 in vitro. Antiviral Research. 2020
29. Possible coronavirus drug identified by Monash University scientists. 2020.
30. Ursula B Kaiser et al.: Our Response to COVID-19 as Endocrinologists and Diabetologists, The Journal of Clinical Endocrinology & Metabolism, Volume 105, Issue 5, 31 2020.
31. Caly, L. et al: The FDA-approved drug ivermectin inhibits the replication of SARS-CoV-2 in vitro Antiviral Research ELSEVIER Volume 178, 2020, 104787 pags. 1 a 4
32. Patel, Amit et al: Usefulness of Ivermectin in COVID-19 Illness. Department of Bioengineering, University of Utah, Salt Lake City. MMEHRA@BWH.HARVARD.EDU
33. Cynthia A. Guzzo et al. Safety, Tolerability, and Pharmacokinetics of Escalating High Doses of Ivermectin in Healthy Adult Subjects. Journal of Clinical Pharmacology, 2002;42:1122-1133 American College of Clinical Pharmacology
34. Guang Chen Clinical and immunological features of severe and moderate coronavirus disease 2019. J Clin Invest. 2020.
35. Kelvin Kai-Wang To: Temporal profiles of viral load in posterior oropharyngeal saliva samples and serum antibody responses during infection by SARS-CoV-2: an observational cohort study., www.thelancet.com/infection Published online March 23, 2020
36. Sri Santosh T, Parmar R, Anand H, et al. (April 17, 2020) A Review of Salivary Diagnostics and Its Potential Implication in Detection of Covid-19. Cureus 12(4): e7708.
37. O. Z. Baraka B. M. Mahmoud C. K. Marschke T. G. Geary M. M. A. Homeida J. F. Williams: Ivermectin distribution in the plasma and tissues of patients infected with *Onchocerca volvulus*. Eur J Clin Pharmacol (1996) 50 : 407-410 © Springer-Verlag 1996
38. G. Edwards, A. Dingsdale, N. Helsby, M. L'E. Orme, and A. M. Breckenridge: The Relative Systemic Availability of Ivermectin After Administration as Capsule, Tablet, and
39. Oral Solution. Department of Pharmacology and Therapeutics, The University of Liverpool, Liverpool. Eur J Clin Pharmacol (1988) 35:681-684
40. Ceccotti, E.: El COVID 19, la saliva y la mucosa lingual. Panondonto.com.ar (2020)
41. Supinda Bunyanich, Anh Do, Alfin Vicencio: Nasal Gene Expression of Angiotensin-Converting Enzyme 2 in Children and Adults. JAMA Published online May 20, 2020
42. Carvallo, Héctor; Hirsch, Roberto; Fajardo, Francisco; Ciruzzi, Juan M.; y Martín, Mirta: Ivermectina, corticoides, aspirina y enoxaparina en el tratamiento del covid 19. Revista Científica Multidisciplinaria del Hospital A. Eurnekián. Edición especial nro. 5 covid-19 (abril 2020) pp16-27.
43. Hirsch, Roberto; Nacucchio, Marcelo; Cassará, María L.; Ghirardi, Patricio; y Carvallo, Héctor E.: Ivermectina su utilidad en profilaxis, terapéutica e inmunidad contra el covid 19. Revista Científica Multidisciplinaria del Hospital A. A. Eurnekián. Edición especial nro. 6 covid-19 pp. 2-42 (Mayo 2020).
44. Carvallo, Héctor; Hirsch, Roberto; Fajardo, Francisco; Ciruzzi, Juan; y Martín Mirta: Ivermectina, corticoides, aspirina y enoxaparina en COVID 19. Rev. Educándonos. Arch. Arg. Derm. 2020; 7 (2): 40-42.